

EUROPEAN JOURNAL OF

ORAL IMPLANTOLOGY

*Official publication of the British Society of Oral Implantology (BSOI),
the Italian Society of Oral Surgery and Implantology (SICOI),
the Danish Society for Oral Implantology (DSOI),
the German Dental Implant Association (DGI),
and the Spanish Society of Implantology (SEI)*

SPECIAL REPRINT

Markus Schlee, Marco Esposito

*Human dermis graft versus autogenous connective tissue grafts for thickening soft tissue
and covering multiple gingival recessions: 6-month results from a preference clinical trial*

EJOI



VOLUME 4 / ISSUE 2
SUMMER 2011

An Ever-Expanding Range Of Trusted Clinical Solutions

Hard Tissue Augmentation



Puros®
Block Allograft



Puros® Cancellous
Particulate Allograft



Puros® Cortical
Particulate Allograft

Barrier Membranes



CopiOs® Pericardium
Membrane



BioMend® and BioMend® Extend™
Absorbable Collagen Membranes



Zimmer®
Socket Repair Membrane

Soft Tissue Augmentation



Puros® Dermis
Allograft Tissue Matrix

Zimmer Dental Regenerative Products.

Learn more at www.zimmerdental.com

To receive our eNews visit us at

www.zimmerdental.com/news_eNewsletterSignUp.aspx

Please note that not all products are registered or available in every country. Please check with a Zimmer Dental representative for availability and additional information.

© 2010 Zimmer Dental Inc.



www.zimmerdental.com

Markus Schlee, Marco Esposito

Human dermis graft versus autogenous connective tissue grafts for thickening soft tissue and covering multiple gingival recessions: 6-month results from a preference clinical trial



Markus Schlee, DDS
Private practice, Forchheim,
Germany

**Marco Esposito, DDS,
PhD**

Freelance researcher and
Associate Professor,
Department of Biomaterials,
The Sahlgrenska Academy
at Göteborg University,
Göteborg, Sweden

Correspondence to:

Dr Markus Schlee,
Bayreuther Strasse 39,
91301 Forchheim, Germany
Email: markus.schlee@
32schoenezaehne.de

Key words *aesthetic, connective tissue graft, gingival recession, preference controlled clinical trial, soft tissue augmentation*

Purpose: To evaluate whether a human dermis graft (HDG) could be used instead of an autogenous connective tissue graft (ACT) to increase gingival thickness and to cover multiple gingival recessions.

Materials and methods: Forty-two consecutive patients with multiple gingival recessions were offered the option to have their recessions covered either with ACTs harvested from their palate or with HDGs. Outcome measures were complications, gingival recession changes (REC), gingival bio-type changes (BIO), probing attachment level changes (PAL), probing pocket depth changes (PPD) and keratinised mucosa height changes (KER) evaluated by an independent and masked assessor after 6 months.

Results: Twenty-one patients with 110 recessions opted for ACTs and 21 patients with 160 recessions opted for HDGs. No patients dropped out. Only one minor complication occurred at one HDG-treated site. Recessions significantly decreased in both groups (2.7 mm for ACT and 2.0 mm for HDG), however, ACTs resulted in a statistically significantly improved root coverage and CAL of 0.5 mm, as well as 18% more root coverage than HDGs.

Conclusions: HDGs can be an effective alternative to ACTs for covering exposed roots and increasing soft tissue thickness, especially when many recessions have to be treated in the same mouth, though they may provide slightly less root coverage than ACTs.

Conflict-of-interest statement: *This study was partially supported by Tutogen Medical GmbH, Neunkirchen an Brand, Germany.*

■ Introduction

Exposed root surfaces can be unaesthetic, more prone to hypersensitivity and root caries, and more difficult to be maintained clean of dental plaque. Gum recessions can be caused by high pressure while tooth brushing and iatrogenic dental treatments such

as orthodontic tooth movement. A thin gingival bio-type and a buccal position of the tooth are the most relevant factors associated with increased gingival recessions, therefore a thick gingiva is less prone to recession. Various procedures are used for root coverage to thicken the buccal gingiva and improve aesthetics. These techniques include various lateral

or coronal sliding flaps¹, guided tissue regeneration^{2,3}, and implantation of grafts^{3,4}. A subepithelial connective tissue graft (ACT) harvested from the palate has been introduced to increase root coverage and gum thickness^{2,5}. The ACT is placed underneath a split-thickness flap which can be coronally, laterally or not mobilised, thus the ACT is at least partially covered by the flap. Because of the good clinical success and colour match, ACTs have been regarded as the gold standard^{3,4}. However, bleeding of the donor site, hyposensitivity of the palate, and postoperative pain and discomfort can occur. For patients with multiple recessions it may be difficult to harvest enough connective tissue from the palate and multiple surgeries may be necessary. Therefore, it might be advantageous to replace autogenous ACT with an alternative graft. Different types of human acellular freeze dried human dermis are currently used as homologue transplants to avoid a second site surgery⁶⁻⁸.

The aim of this preference controlled clinical trial was to evaluate whether a solvent dehydrated sterile human dermis graft (HDG) could be used instead of an ACT to increase gingival thickness and to cover multiple gingival recessions.

■ Materials and methods

Any patient, 18 years old or older, requesting gingival coverage at more than one tooth affected by Miller Class I and II recessions (no visible loss of interdental papilla and distance between cemento-enamel junction [CEJ] to bone crest ≤ 2.5 mm measured on periapical radiographs, though, when present, Miller class III and IV recessions were also treated and considered in the analyses)⁹, and able to sign an informed consent form, was eligible for inclusion in this trial. Patients were not admitted to the study if any of the following exclusion criteria were present:

- any pathologic systemic condition
- smokers (ex-smokers could be included if not smoking for at least 6 months)
- affected by periodontitis
- poor oral hygiene and motivation (plaque and bleedings scores $< 15\%$ before surgery)
- pregnant
- participant in other clinical studies within the last 6 months before surgery.

Patients were recruited and treated in one private practice by the same operator (MS), using similar procedures. The study was approved by the Ethics Commission International Freiburg, Germany (study code: TM-MS-2006-01; feci Code: 010/1462). The principles outlined in the Declaration of Helsinki on clinical research involving human subjects were adhered to. Patients were informed that they could choose between two different treatment options. Any potential advantages and disadvantages with each technique were explained by the operator, and the patients were left to choose what they preferred. All patients signed an informed consent form prior to being enrolled in the trial. Following initial examination, patients were instructed in oral hygiene and a professional tooth cleaning was delivered as required.

■ Surgical procedure

Besides complete root coverage, the aim of the surgery was to increase the thickness of the gingival tissue. All surgeries were performed by the same operator (MS). No antibiotics were provided. After local anaesthesia, the exposed roots were scaled and planed to the bottom of the pocket with rotating burs, ultrasonic instruments and curettes. Deeper instrumentation was avoided to prevent damage to the periodontal ligament. In addition, prominent roots were flattened. No chemical root conditioning was performed. After sulcular incision, a coronally displaced split-thickness flap was performed without releasing incision according to the incision outline described by Zucchelli¹⁰, though a complete split-thickness flap was elevated. The flap was considered to be mobilised enough when it stayed passively at a level slightly coronal to the CEJ. According to patient preference, subepithelial connective tissue grafts (Fig 1) were harvested from one or two palatal sides, depending on the amount of tissue needed, or human dermis acellular allografts (Fig 2) were used.

Tutoplast® Dermis Allograft Tissue Matrix (Tutogen Medical, Neunkirchen am Brand, Germany [now available as Puros® Dermis, Zimmer Dental, Carlsbad, CA, USA]) was used as a human dermis graft. The allograft retains the natural collagen matrix and mechanical properties of native dermis¹¹. The

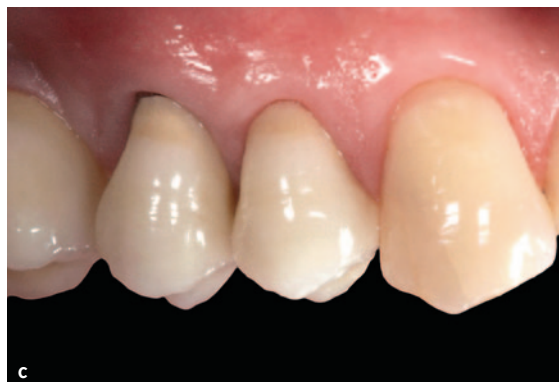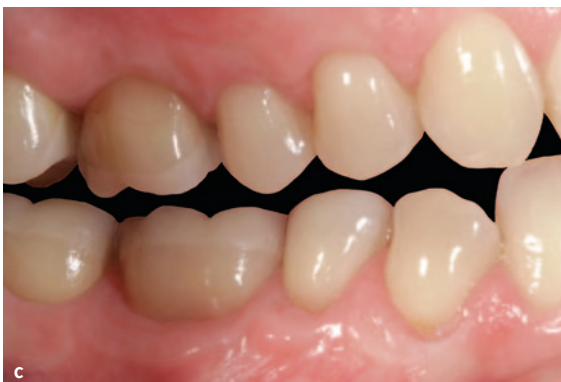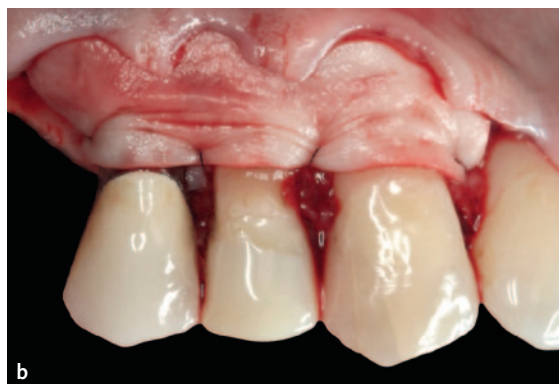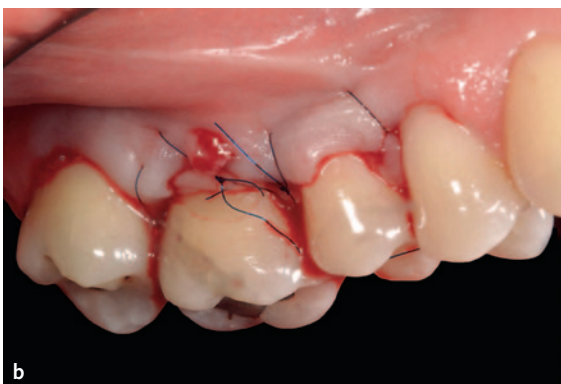


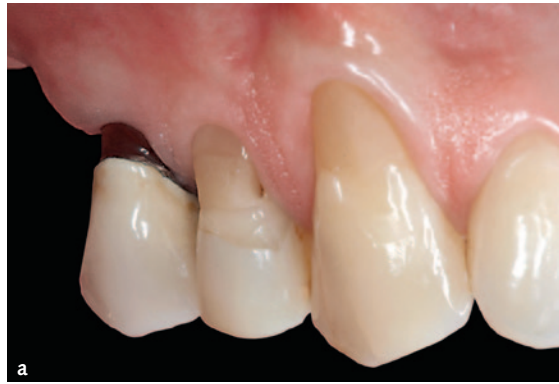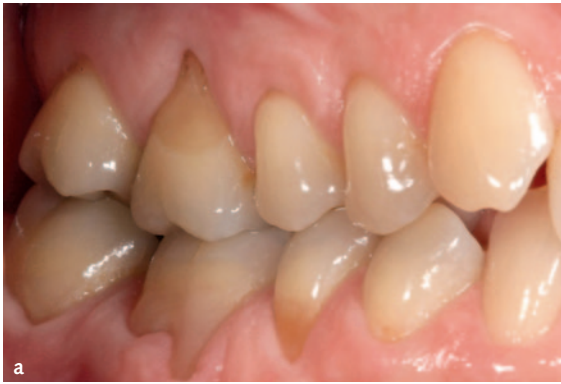Fig 1 Clinical pictures of one patient included in the connective tissue graft group: a) preoperative situation, b) just after suturing, c) after 6 months.

Fig 2 Clinical pictures of one patient included in the human dermis group: a) preoperative situation, b) after positioning of the human dermis graft, c) after 6 months.

tissue processing also inactivates bacterial, viral and prion contamination and eliminates antigenicity. The solvent-dried material is packaged with the absence of residual antibiotics and terminally sterilised by low-dose gamma irradiation. The graft was rehydrated for 30 minutes in sterile saline, adapted in size, placed underneath the flap and fixed around the recipient teeth with sling sutures (Prolene, 6-0, Braun, Melsungen, Germany). The most coronal position was about 1 mm below the CEJ. The flap was coronally advanced to completely cover the graft and was also fixed with sling sutures to accomplish a precise adap-

tation around teeth. Suture knots were placed on the lingual aspect to decrease patient discomfort during removal.

When subepithelial connective tissue grafts were used, a single incision parallel to the gingival margin using a scalpel with a 15c blade was made in the palate¹². After the separation of the tissue graft with two horizontal and two vertical incisions, the connective tissue was removed, leaving the periosteum attached to the bone. The donor region was sutured and epithelium was carefully removed from the graft. The ACTs were handled exactly in the same manner as the HDGs.

Patients were instructed to avoid any mechanical trauma to the wound and to rinse with chlorhexidine mouthwash (0.12%) twice a day for 1 minute, for 4 weeks. Ibuprofen (400 mg) was prescribed as an analgesic and anti-inflammatory medication. Sutures were removed after 2 weeks and patients were recalled 1, 2 and 6 months after surgery for professional supra-gingival tooth cleaning and reinforcement of motivation for good oral hygiene. Patients were also instructed to use a gentle roll technique with soft brushes for brushing their teeth.

The present study tested the null hypothesis that there were no differences between the two procedures against the alternative hypothesis of a difference. Outcome measures were:

- **Complication:** any complication that occurred during or after the grafting procedure for the entire follow-up period.
- **Gingival recession changes (REC):** measured from the CEJ to the most apical position of the gingiva on the buccal aspect of the root. It was expressed in percentages according to the following formula: $100 \times ([\text{REC baseline} - \text{REC 6 months}] / \text{REC baseline})$. When not visible, the CEJ position was estimated by the outcome assessor.
- **Gingival biotype changes (BIO):** gingiva was considered to be thick when the probe was not visible through the tissue; if visible, it was classified as thin biotype.
- **Probing pocket depth changes (PPD):** measured from the most apical position of the gingiva on the buccal aspect of the root to the bottom of the gingival sulcus.
- **Probing attachment level changes (PAL):** calculated by following the formula: $\text{PAL} = \text{REC} + \text{PPD}$.
- **Keratinised mucosa width changes (KER):** measured from the gingival margin to the mucogingival junction (MGJ).

All clinical periodontal measurements were made prior to surgery (baseline) and 6 months after with a pressure sensitive periodontal probe (PCP-UNC 15 probe, Hu-Friedy, USA) using a calibrated force of 0.3 Ncm to the nearest 0.5 mm by one independent, experienced and blinded dental hygienist (Tatjana Huck).

No sample size calculation was performed. A biostatistician with expertise in dentistry analysed the data, without knowing the group codes. The patient

was the statistical unit of the analyses. Differences in the proportion of patients with complications were compared between the groups using the Fisher exact probability test. Differences of means at patient level for continuous outcomes between groups were compared by *t* tests. Comparisons between the baseline measurements and 6 months after augmentation were made by paired *t* tests. All statistical comparisons were conducted at the 0.05 level of significance.

■ Results

Forty-two patients who were interested in having their recession treated for aesthetic reasons were considered eligible and were consecutively enrolled in the trial. Twenty-one patients opted to donate their own tissues and 21 preferred to be treated with a human dermis. All patients were treated according to their own preference. Patients were treated between September 2005 and January 2010. No patient dropped out. Data from all patients were included in the statistical analyses and no deviation from the study protocol occurred.

The main baseline patient characteristics are presented in Table 1. There were no apparent significant baseline imbalances between the two groups with the exception of more recessions per patient in the group treated with human dermis (7.6 versus 5.2 mm).

The main results 6 months after the augmentation procedure are summarised in Table 2. Only one minor postoperative complication was observed during the entire follow-up period: at suture removal, 7 days after grafting, a HDG was exposed. This thin biotype site with no keratinised gingiva showed dermis exposition due to recession of the coronally repositioned flap. The exposed HDG resorbed over time and the recession improved from 4 to 2.5 mm. After 6 months, the site was still characterised as a thin biotype but about 1 mm of keratinised gingiva was present.

Six months after grafting, recessions in both groups were statistically significantly reduced (2.7 mm for ACTs and 2.0 mm for HDGs; Table 3). On average, there was 0.5 mm less recession at ACT-treated sites, and this was statistically significant (Table 2). More specifically, ACTs determined 17.8% more root coverage than HDGs, which was statistically significant (Table 2).

Table 1 Baseline patient and site characteristics.

	ACT (n = 21)	HDG (n = 21)
Number of females	17	16
Age (range)	45.6 (24-65)	47.3 (25-70)
Mean number of recessions per patient	5.2	7.6
number of recessions	110	160
Number of maxillary incisors	6	26
Number of maxillary canines	18	28
Number of maxillary premolars	23	40
Number of maxillary molars	12	24
Number of mandibular incisors	18	11
Number of mandibular canines	12	6
Number of mandibular premolars	14	18
Number of mandibular molars	7	7
Number of Miller class I recessions	67	108
Number of Miller class II recessions	30	33
Number of Miller class III recessions	12	18
Number of Miller class IV recessions	1	1
Number of thin biotype sites	62	97
Number of thick biotype sites	48	63
Mean biotype proportion thin/thick (SD)	0.30 (0.30)	0.34 (0.29)
Mean recessions mm (SD)	2.90 (0.84)	2.76 (0.76)
Mean keratinised mucosa heights mm (SD)	1.70 (1.09)	2.12 (0.94)
Mean probing pocket depths mm (SD)	1.61 (0.57)	1.79 (0.48)
Mean probing attachment levels mm (SD)	4.51 (1.11)	4.55 (1.06)

Table 2 Summary of the main results 6 months after grafting and difference between groups.

	ACT (n = 21)	HDG (n = 21)	Difference (standard error)	95% CI	P value
Proportion of patient with complications	0	0.048 (0.05)	0.048 (0.05)	***	1.00
Number of thin biotype sites*	10	20			
Number of thick biotype sites*	100	140			
Mean biotype proportion thin/thick (SD)	0.89 (0.30)	0.88 (0.16)	0.02 (0.07)	-0.13, 0.17	0.819
Mean recessions mm (SD)	0.21 (0.38)	0.73 (0.46)	-0.52 (0.13)	-0.78, -0.26	<0.001**
Root coverage in percentage (SD)	93.6% (11.2)	75.8% (15.6)	17.8% (4.2)	9.31, 26.2	<0.001**
Mean keratinised mucosa heights mm (SD)	3.43 (1.37)	3.07 (0.88)	0.37 (0.36)	-0.35, 1.08	0.307
Mean probing attachment levels mm (SD)	1.75 (0.62)	2.27 (0.63)	-0.52 (0.19)	-0.91, -0.13	0.001**
Mean probing pocket depths mm (SD)	1.54 (0.48)	1.55 (0.38)	-0.01 (0.14)	-0.27, 0.27	0.998

*Based on site data (clustered within patients); no analysis undertaken

**Statistically significant values $P < 0.001$

***Exact calculation not possible with zero count cells

Table 3 Comparison of clinical outcomes in mm (SD) at baseline and after 6 months for the two study groups (n = 21 in each group).

	ACT REC	HDG REC	ACT BIO	HDG BIO	ACT KER	HDG KER	ACT PAL	HDG PAL	ACT PPD	HTG PPD
Baseline	2.90 (0.84)	2.76 (0.76)	0.30 (0.30)	0.34 (0.29)	1.70 (1.09)	2.12 (0.94)	4.51 (1.11)	4.55 (1.06)	1.61 (0.57)	1.79 (0.48)
6 months	0.21 (0.38)	0.73 (0.46)	0.89 (0.30)	0.88 (0.16)	3.43 (1.37)	3.07 (0.88)	1.75 (0.62)	2.27 (0.63)	1.54 (0.48)	1.55 (0.38)
Difference	2.68 (0.71)	2.03 (0.64)	0.60 (36)	0.54 (0.25)	1.73 (1.60)	0.95 (1.01)	2.75 (0.95)	2.28 (0.98)	-0.07 (0.47)	-0.24 (0.63)
95% CI	2.36, 3.01	1.74, 2.33	0.43, 0.76	0.42, 0.65	1.00, 2.46	0.49, 1.41	2.32, 3.19	1.83, 2.72	-0.28, 0.14	-0.53, 0.05
P value	<0.001*	<0.001*	<0.001*	<0.001*	<0.001*	<0.001*	<0.001*	<0.001*	0.51	0.10

*Statistically significant values

Both procedures thickened biotype in the same way (Tables 1–3) with no differences between the two procedures (Table 2).

Both procedures were able to increase the height of keratinised mucosa (on average 1.73 mm for ACTs and 0.95 mm for HDGs; Table 3), the difference between groups being not statistically significant (Table 2). Probing attachment levels significantly improved for both groups (on average 2.75 mm for ACTs and 2.28 mm for HDGs; Table 3), though ACTs provided, on average, an additional significant improvement of 0.52 mm (Table 2).

There were no significant changes for probing pocket depths over time (Table 3) and between groups (Table 2).

■ Discussion

This patient preference trial was designed to assess whether HDGs could replace autogenous ACTs for treating multiple root recessions. Both procedures were effective in covering the exposed roots and in increasing soft tissue thickness, though slightly better clinical results were obtained using ACTs. When attempting to compare the present results with those of similar trials, the present authors could identify only four randomised controlled trials (RCTs)^{13–16} comparing ACTs with another acellular dermal matrix graft (Alloderm, Life Cell Corporation, The Woodlands, TX, USA), which were evaluated in a systematic review⁷. The meta-analyses of these four trials (60 patients per group) for root coverage and KER did not show any statistically significant differences 6 months after grafting between the two different procedures. When comparing directly the same HDGs used in the present investigation (Tutoplast Dermis) with the previously mentioned acellular dermal matrix graft (Alloderm)

in one split-mouth RCT including 14 patients with 56 recessions⁸, no statistically significant difference could be observed after 6 months for root coverage, KER, PAL and PPD.

The main limitations of the present study are the lack of randomisation, the strict inclusion criteria, the lack of assessment of postoperative pain, the lack of colour match evaluation of the grafted areas, and the small sample size. The clinical investigator decided to let patients choose the intervention they preferred because this was considered to be the simpler way to run this trial in a private practice setting. However, patients can be influenced by the clinician's views, therefore group allocation is at a high risk of bias. Curiously, the patient choice generated two groups with an equal number of patients. Though group allocation was not performed at random, all assessments were performed by a masked outcome assessor.

The results of this study may not be generalised with confidence to other populations due to the strict inclusion criteria and lack of randomisation. It is not possible to definitively recommend any of the tested procedures since personal values are involved. Patients should be correctly informed that there could be more postoperative pain/discomfort and a slightly better (18% more gingival coverage) aesthetic outcome when using their own tissues, and should decide by themselves what they prefer.

■ Conclusions

Human dermis grafts could be an alternative treatment option to autogenous connective tissue grafts for covering exposed roots and increasing soft tissue thickness. While HDGs provided slightly inferior root coverage, they may cause less postoperative pain/discomfort.

References

1. Cairo F, Pagliaro U, Nieri M. Treatment of gingival recession with coronally advanced flap procedures: a systematic review. *J Clin Periodontol* 2008;35:136-162.
2. Muller HP, Eger T, Schorb A. Gingival dimensions after root coverage with free connective tissue grafts. *J Clin Periodontol* 1998;25:424-430.
3. Oates TW, Robinson M, Gunsolley JC. Surgical therapies for the treatment of gingival recession. A systematic review. *Ann Periodontol* 2003;8:303-320.
4. Rocuzzo M, Bunino M, Needleman I, Sanz M. Periodontal plastic surgery for treatment of localized gingival recessions: a systematic review. *J Clin Periodontol* 2002;29(Suppl 3):178-194; discussion 195-196.
5. Langer B, Langer L. Subepithelial connective tissue graft technique for root coverage. *J Periodontol* 1985;56:715-720.
6. Harris RJ. A comparative study of root coverage obtained with an acellular dermal matrix versus a connective tissue graft: results of 107 recession defects in 50 consecutively treated patients. *Int J Periodontics Restorative Dent* 2000;20:51-59.
7. Gapski R, Parks CA, Wang HL. Acellular dermal matrix for mucogingival surgery: a meta-analysis. *J Periodontol* 2005;76:1814-1822.
8. Barker TS, Cueva MA, Rivera-Hidalgo F, Beach MM, Rossmann JA, Kerns DG, Crump TB, Shulman JD. A comparative study of root coverage using two different acellular dermal matrix products. *J Periodontol* 2010;81:1596-1603.
9. Miller PD, Jr. A classification of marginal tissue recession. *Int J Periodontics Restorative Dent* 1985;5:8-13.
10. Zucchelli G, De Sanctis M. Treatment of multiple recession-type defects in patients with esthetic demands. *J Periodontol* 2000;71:1506-1514.
11. Hinton R, Jinnah RH, Johnson C, Warden K, Clarke HJ. A biomechanical analysis of solvent-dehydrated and freeze-dried human fascia lata allografts. A preliminary report. *Am J Sports Med* 1992;20:607-612.
12. Hürzeler MB, Weng D. A single-incision technique to harvest subepithelial connective tissue grafts from the palate. *Int J Periodontics Restorative Dent* 1999;19:279-287.
13. Aichelmann-Reidy ME, Yukna RA, Evans GH, Nasr HF, Mayer ET. Clinical evaluation of acellular allograft dermis for the treatment of human gingival recession. *J Periodontol* 2001;72:998-1005.
14. Novaes AB, Jr., Grisi DC, Molina GO, Souza SL, Taba M, Jr., Grisi MF. Comparative 6-month clinical study of a subepithelial connective tissue graft and acellular dermal matrix graft for the treatment of gingival recession. *J Periodontol* 2001;72:1477-1484.
15. Tal H, Moses O, Zohar R, Meir H, Nemcovsky C. Root coverage of advanced gingival recession: a comparative study between acellular dermal matrix allograft and subepithelial connective tissue grafts. *J Periodontol* 2002;73:1405-1411.
16. Barros RR, Novaes AB, Grisi MF, Souza SL, Taba MJ, Palioto DB. A 6-month comparative clinical study of a conventional and a new surgical approach for root coverage with acellular dermal matrix. *J Periodontol* 2004;75:1350-1356.

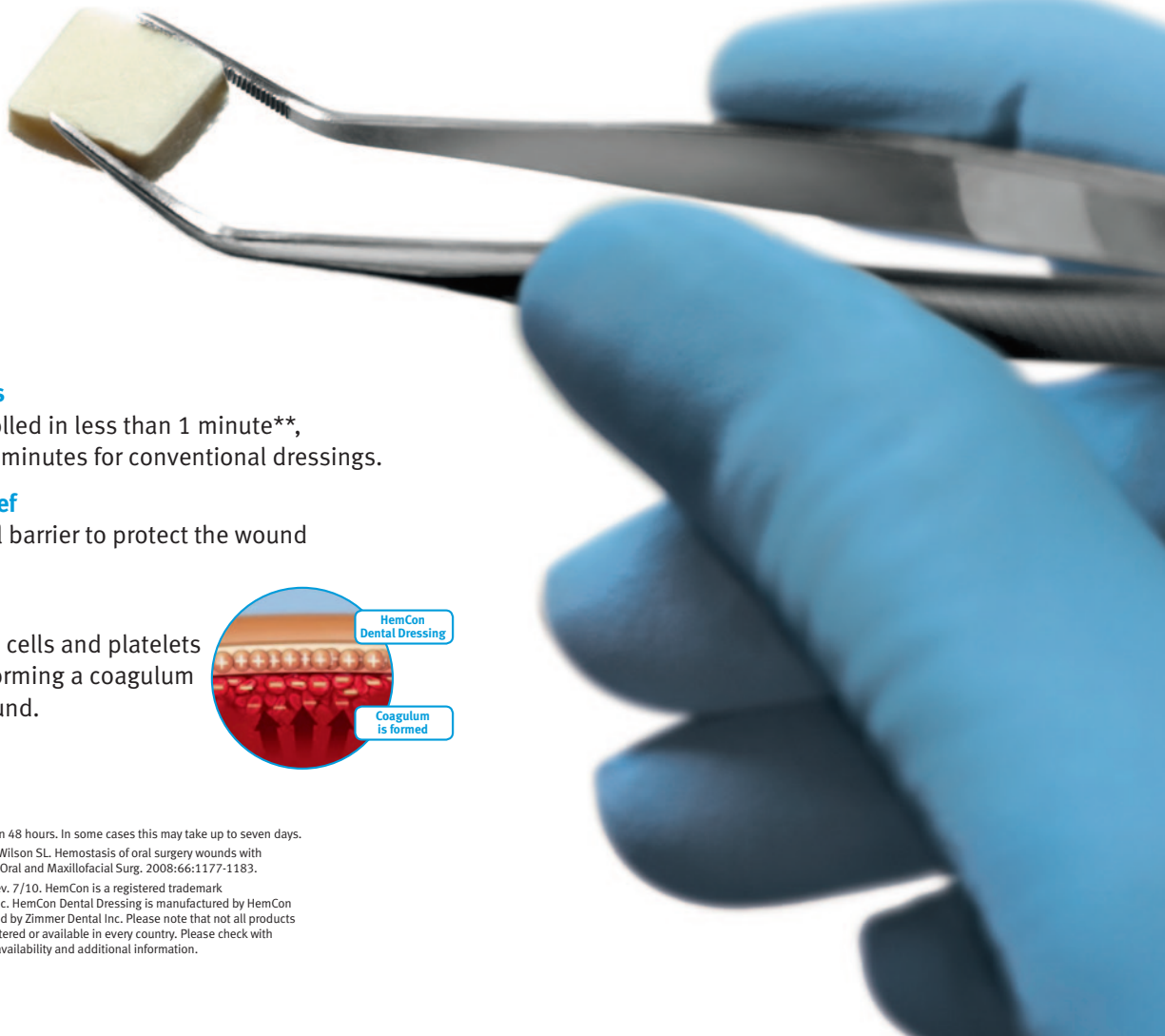
HemCon[®] – Stops bleeding.

HemCon Dental Dressing is self-adhesive and self-dissolving.

After one minute – the bleeding has stopped.

After 48 hours – dressing has dissolved.*

NEW!



- **Faster hemostasis**

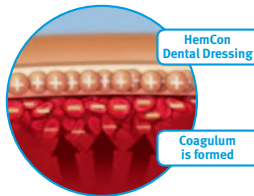
Bleeding is controlled in less than 1 minute**, compared to 9.53 minutes for conventional dressings.

- **Effective pain relief**

Creates a physical barrier to protect the wound from irritation.

- **How it works**

Attracts red blood cells and platelets to the dressing, forming a coagulum that seals the wound.



* The dressing usually dissolves within 48 hours. In some cases this may take up to seven days.

** Malmquist JP, Clemens SC, Oien HJ, Wilson SL. Hemostasis of oral surgery wounds with HemCon Dental Dressing. Journal of Oral and Maxillofacial Surg. 2008;66:1177-1183.

©2010 Zimmer Dental Inc. 2346, Rev. 7/10. HemCon is a registered trademark of HemCon Medical Technologies, Inc. HemCon Dental Dressing is manufactured by HemCon Medical Technologies and distributed by Zimmer Dental Inc. Please note that not all products and regenerative materials are registered or available in every country. Please check with a Zimmer Dental representative for availability and additional information.

I am Zimmer. I know that actions speak louder than words but I want you to have this in writing. I am committed to your success. To showing you that Zimmer stands for quality, service and innovation. I believe in providing the unique products and services you need to support and grow your business. Like all of us here, I am responsible for ensuring the Zimmer experience is one you can count on. Let me prove it to you one step at a time. **I am Zimmer and I am here.**



ZIMMER

Anna-Maria Gisske
Marketing & Admin. Assistant
Europe, Middle East & Africa

To learn more about how Zimmer Dental can establish a lasting partnership with your practice, please visit us online at www.zimmerdental.com or contact us at dental.marketing@zimmer.com.




www.zimmerdental.com



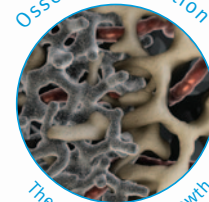
The Best Thing Next To Bone.™

Introducing Trabecular Metal™ Material to implant dentistry.

Trabecular Metal Material

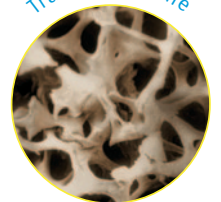


Osseoincorporation



The process of ingrowth

Trabecular bone



Artistic Rendering

Zimmer Dental is evolving implant dentistry with the introduction of *Trabecular Metal Material*. With over a decade of clinical use in orthopaedics, *Trabecular Metal Material*'s highly biocompatible tantalum and 3D porous cellular structure have been clinically proven to create the potential for clinical ingrowth, or osseoincorporation:¹ Bone's ability to not only grow into the pores and around the struts, but also to interconnect, is what makes *Trabecular Metal Material* *The Best Thing Next To Bone*.

To learn more, talk to a Zimmer sales representative or visit <http://TrabecularMetal.zimmerdental.com>.

1. Bobyn JD, Poggie RA, Krygier JJ, Lewallen DF, Hanssen AD, Lewis RJ, Unger AS, O'Keefe TJ, Christie MH, Nasser S, Wood JE, Stulberg SD, Tanzer M. Clinical validation of a structural porous tantalum biomaterial for adult reconstruction. *J Bone Joint Surg*. 2004;86-A(Suppl 2):123-129. 2. Black J. Biological performance of tantalum. *Clin Mater*. 1994;16:167-173. 3. Bobyn JD. UHMWPE: the good, bad, & ugly. Fixation and bearing surfaces for the next millennium. *Orthop*. 1999;22(9):810-812.



www.zimmerdental.com

©2010 Zimmer Dental Inc.